



Surgical Considerations of Implant Placement in Impacted Canines - Case Series

Vatsal Jaipuria, Watchariyaporn Thasai, Mary Kang, Stuart Froum, Sang-Choon Cho, Leena Palomo
Ashman Department of Periodontology and Implant Dentistry, New York University College of Dentistry



INTRODUCTION

The impaction of maxillary canines is a common phenomenon. In the literature, different teeth impactions show a prevalence ranging from 2.9% (1) to 20% (2) Without the consideration of wisdom teeth, the maxillary canine has the highest rate and severity of impaction in the vertical, horizontal and angular positions (2). The prevalence in the general population is approximately 2%, with a palatal/buccal ratio of 8:1(3).

The clinical presentation oftentimes is found in conjunction with other tooth abnormalities such as microdontia of the maxillary lateral incisor, retention of the deciduous canine or presence of a space where the impacted tooth should have erupted. These clinical manifestations result in esthetic concerns that encourage patients to seek dental treatment.

To correct these undesired events, impacted canines can be brought into occlusion with orthodontic therapy or re-implantation, but this depends upon the position of the impacted canine within the maxilla, the severity of impaction, and the presence of ankylosis (4). When these treatment options are not clinically feasible or the patient does not desire orthodontic treatment, then surgical removal of the impacted canine is recommended and subsequent bone grafting with implant placement (5) may be offered as a viable treatment option to replace the missing tooth.

The aim of this case series is to present the step-by-step diagnostic and clinical procedures followed to manage a complex bony defect associated with an impacted canine extraction, via site development and implant placement in an adult female with a history of failed orthodontic treatment.

MATERIALS AND METHODS

A 36 years-old caucasian female patient presented to the New York University College of Dentistry Ashman Department of Periodontology and Implant Dentistry with a chief complaint of wanting to replace a missing maxillary canine. The left maxillary canine was impacted and had undergone two years of orthodontic treatment in a private clinic without successful alignment in the arch, it was presumed ankylosed and referred to the implant clinic for evaluation of extraction and replacement by an implant-supported restoration. The patient did not have any medical conditions and was not taking any medications.

Clinical intraoral examination revealed the presence of a gold orthodontic chain emerging from the right hemi palate soft tissue as well as a wide mesio-distal space in the position of the maxillary right canine. No deciduous tooth was present. In the aesthetic evaluation of the case, a discrepancy between the tooth size and the maxillary arch extension was diagnosed, resulting in anterior diastemas between her teeth, which the patient wanted to address after inquiring about it.

An aesthetic diagnostic wax-up of the case was done, and the patient was sent for a Cone Beam Computerized Tomography (CBCT) with the aid of a Radiographic Guide replacing the canine in its ideal position. A 3-D Printed model was created from the STL-file of the CBCT, showing the exact 3-dimensional

position of the palatally-located impacted tooth. A 12mm implant was simulated in a Simulation Software (Simplant, Dentsply Sirona, USA), and the fact that its ideal apical position interfered with the root of the impacted tooth was noticed. Since the tooth was suspected to be ankylosed, both a complete extraction or a coronectomy were considered as viable treatment options, followed by site-development of the post-extraction defect and a subsequent implant placement with a screw-retained fixed prosthesis.

Treatment options for replacing the missing tooth were discussed with the patient, including a removable partial denture, a fixed partial denture, and an implant-supported crown. The patient understood the pros and cons of each treatment, agreed to the total or partial extraction of the canine with site-development and implant placement.

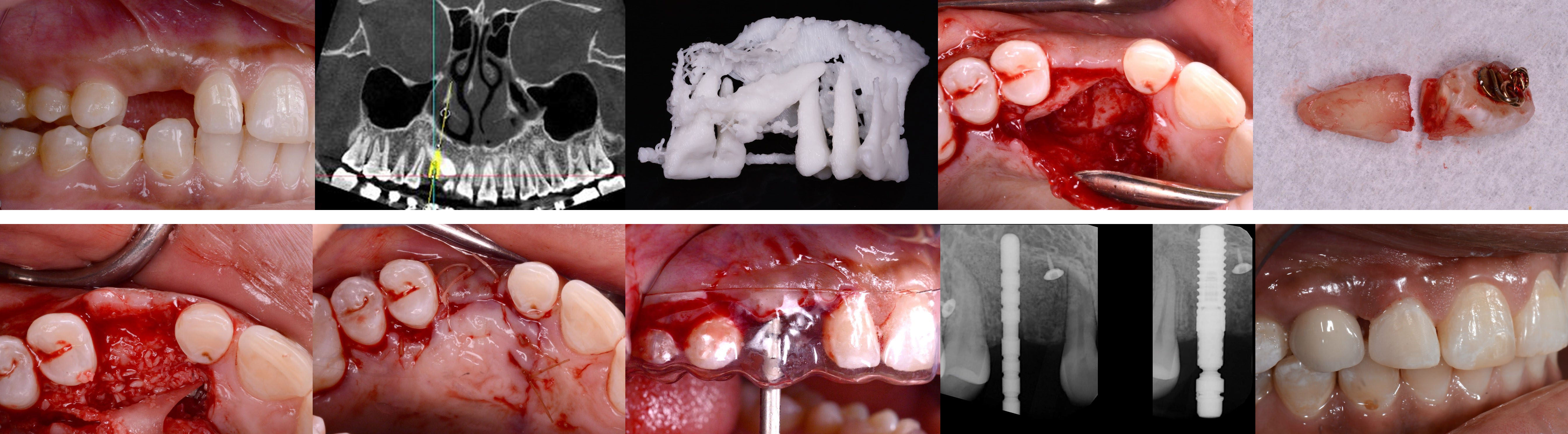
CASE 1 impacted #6 , failed forced eruption, extraction and simultaneous grafting, implant placement

CASE 2 impacted #11 , failed forced eruption, extraction, implant placement and simultaneous grafting

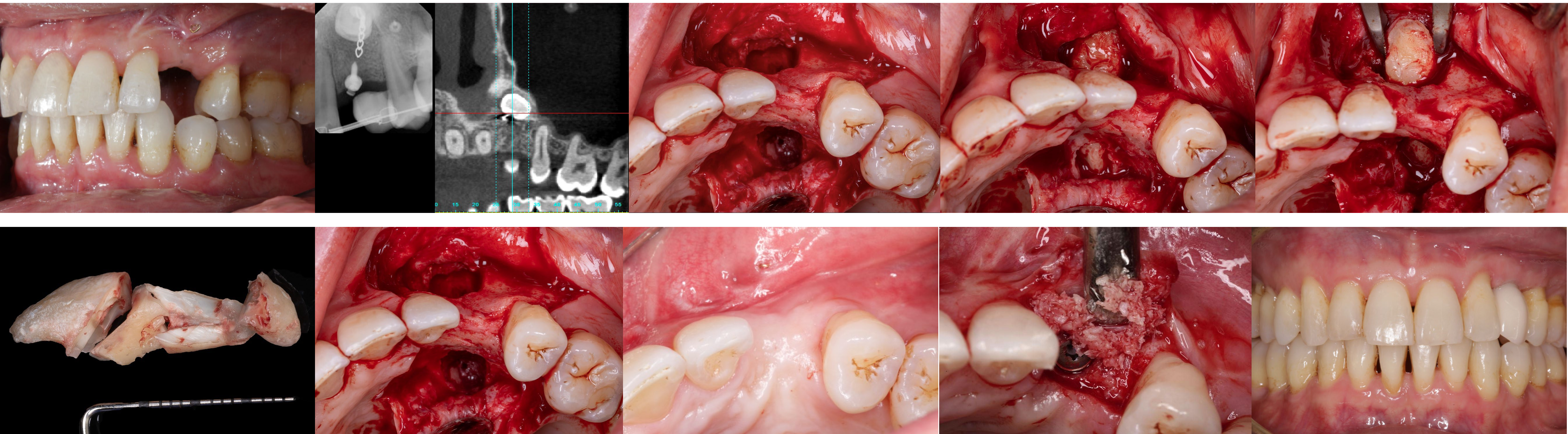
CASE 3 impacted #6, implant placement through root

SEQUENCE OF PROCEDURE

CASE 1 impacted #6 , failed forced eruption, extraction and simultaneous grafting, implant placement



CASE 2 impacted #11 , failed forced eruption, extraction, implant placement and simultaneous grafting



CASE 3 impacted #6, implant placement through root



CONCLUSION

In the present case, a staged approach consisting of extraction of the impacted canine tooth with simultaneous site development using allograft material and re-entry in two months for implant placement proved to be a safe and predictable approach to follow in cases of impacted maxillary canines with previous failed orthodontic treatment. The use of a preoperative 3D-printed model evaluation and treatment rehearsal allowed to perform a more minimally invasive extraction approach, reducing treatment time and therefore morbidity to the patient. More research and comparative studies are necessary to verify the technique and results of the present case report.

REFERENCES

- Uslu, O., Akcam, M. O., Evirgen, S., & Cebeci, I. (2009). Prevalence of dental anomalies in various malocclusions. *American journal of orthodontics and dentofacial orthopedics*; 135(3):328-335
- Al-Abdallah, M., Al-Hadidi, A., Hammad, M., & Dar-Odeh, N. (2018). What factors affect the severity of permanent tooth impaction? *BMC oral health*; 18(1):184.
- Zuiderveld, E. G., Meijer, H. J., Vissink, A., & Raghoobar, G. M. (2015). Immediate placement and provisionalization of an implant after removal of an impacted maxillary canine: two case reports. *International journal of implant dentistry*; 1(1):13.
- Counihan, Kate & Al-Awadhi, Ebrahim & Butler, Jonathan. (2013). Guidelines for the assessment of the impacted maxillary canine. *Dental update*; 40: 770-2, 775.
- Cooke J, Wang HL. Canine impactions: incidence and management. *Int J Periodontics Restorative Dent*. 2006; 26(5):483-491.
- Davarpanah, M., Szmukler-Moncler, S., Rajzbaum, P., Davarpanah, K., Capelle-Ouadah, N., & Demurashvili, G. (2015). Unconventional implant placement. V: Implant placement through impacted teeth; results from 10 cases with an 8- to 1-year follow-up. *International orthodontics*; 13(2):164-180.
- Park N, Bhekare A, Yu YCP, Scolnick J, Loomer PM. Fabrication of Soft Tissue Layers for 3D Printed Models in Dental Implant Education. *J Oral Biol*. 2017; 4(1): 3.